CASE REPORT

Spontaneous Intracranial Hypotension with Cerebral Venous Sinus Thrombosis: A Case Report

Anjani Kumar Sharma*, Kapil Khandelwal **, Shashank Sharma*, Vidit Mathur ****, Pranjal Sharma ***

ABSTRACT

Background: Spontaneous intracranial hypotension (SIH) is secondary headache due to CSF leak leading to orthostatic headache. SIH further complicating and leading to cerebral venous sinus thrombosis (CVST) is rare. This poses unique case scenario and therapeutic dilemma.

Case Presentation: We present a case of 35 year female with chronic postural headache and features suggestive of SIH for few years. She presented with acute worsening of headache and altered behavior for which her MRI brain with venography showed CVST (Superior sagittal, Right Transverse and Sigmoid sinus). She was initially treated with bed rest, high fluid intake, low molecular weight heparin and analgesic (NSAID, Tramadol) with mild relief only. As symptoms persisted, further workup was done and interestingly, she had nontraumatic CSF leak at lumbar region. Later targeted epidural blood patch (EBP) was done at lumbar region and patient got significant relief.

Conclusion: This case highlights early identification of SIH complication as CVST, nontraumatic lumbar site of CSF leak and role of targeted EBP in SIH management.

KEYWORDS: Spontaneous intracranial hypotension, cerebral venous sinus thrombosis, epidural blood patch.

INTRODUCTION

Spontaneous intracranial hypotension (SIH) is usually under diagnosed entity and characterized by orthostatic headache, low CSF pressure <60mm H2O and neuroimaging suggestive of brain sagging with or without demonstrable CSF leakage in absence of history of dural puncture or trauma. Diagnosis is based on criteria laid by ICHD 3rd edition[1] or Schievink criteria[2]. The Hallmark presentation is orthostatic headache. It may be associated with photophobia, neck stiffness, nausea, vomiting, vertigo and tinnitus. Rarer presentation includes cranial nerve palsy, parkinsonian features, cerebellar ataxia, and alteration in consciousness or cognitive impairment due to compression of brain or spinal cord[3].

Complications like cerebral venous sinus thrombosis (CVST) area rare phenomenon in 1-2% cases of SIH[4], leading to unique case scenario and therapeutic dilemma. Here we present a rare case of SIH complicated by CVST.

CASE REPORT:

A 35 year female presented with moderate to severe holocranial headache with recurrent episode of vomiting for 5 days. Headache was continuous with significant increase in sitting and partial relief on lying supine, and on taking NSAIDs and antiemetic. Following this she developed confusion and drowsiness for last 1 day.

In past, she had headache for 5-6 years, which was holocranial, moderate to severe, feeling of stretching sensation and worsening with postural change, more with prolonged standing and associated with occasional vomiting and took NSAIDs for relief. Her previous MRI brain (2 years back) showed descending cerebellar tonsillar herniation, decreased mamillo-pontine distance, decreased ponto-mesencephalic angle, rounding of dural venous sinuses contour.

In view of her worsening symptoms, MRI brain

*DM Neurology, Head, Dept of Neuroscience, CK Birla Hospitals, Jaipur
**DM Neurology, Consultant, CK Birla hospital, Jaipur
***MBBS
****MD Radiodiagnosis, Head, Dept of Radiology, CK Birla Hospital, Jaipur
Corresponding Author:
Dr. Anjani Kumar Sharma
House No. 36, Ram gali No. 7, Raja Park, Jaipur (302004)
Phone - 9414072331, E-mail : anjanijpr@gmail.com

with contrast (Fig 1, 2) was done and showed effaced basal and peri-mesencephalic cistern, prominent peri-optic subarachnoid spaces with distension along the both optic nerve and cerebellar tonsillar herniation. MR Venography (Fig. 3) showed thrombosis in cortical veins, superior sagittal sinus and right transverse and sigmoid sinus.

Blood investigation including CBC, ESR, RFT and LFT and urine routine examination was normal. Further work up revealed ANA, APLA, ACLA, Lupus anticoagulant and viral serology (HBsAg, AntiHCV, HIV) was negative.

In view of neuroimaging features of CVST, she was started on anticoagulation (Enoxaparin) and analgesics (NSAIDs and tramadol) with advice for high fluid intake. Her confusion improved but headache with severe exacerbation in sitting position persisted. As presenting symptoms, past history and imaging also suggested SIH, she was planned for CT myelography to look for evidence of active CSF leakage which may be responsible for her symptomatology. CT myelography (Fig. 4) revealed leakage of intrathecal contrast into the extra-dural spaces on the right side at L1-L2 level (two sites of leakage at this level with proximal one smaller compare to the distal one). Thus, autologous Epidural Blood Patch (EBP) at lumbar region was done. Her headache gradually improved with less frequent orthostatic component. She was discharged on oral anticoagulation and is doing well on follow up visits.

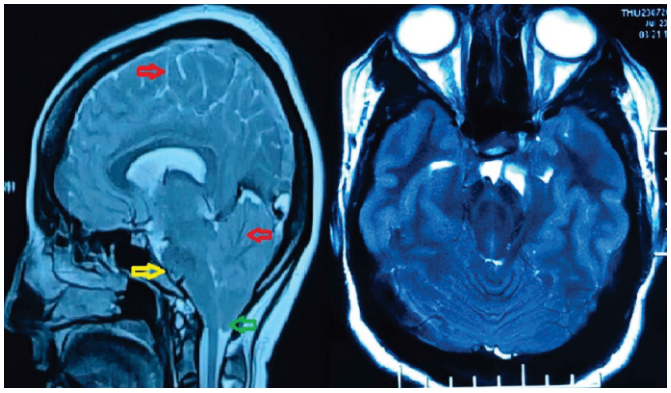

Fig. 1 - MRI brain T2W sagittal image shows reduced CSF space (Red arrow), cerebellar tonsillar herniation (green arrow), flattening of pons, effacement of prepontine cistern and reduced CSF in fourth ventricle (yellow arrow). T2W Axial image shows effacement of perimesencephalic cisterns and compression over midbrain.

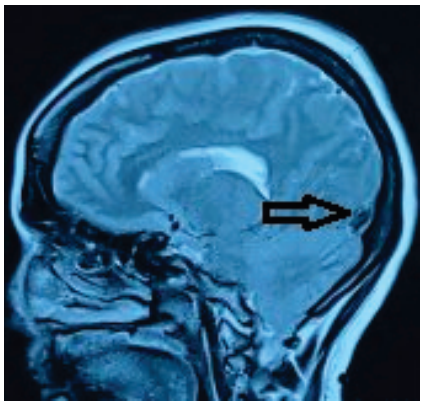

Fig. 2 T2W sagittal image show venous distension sign (black arrow).

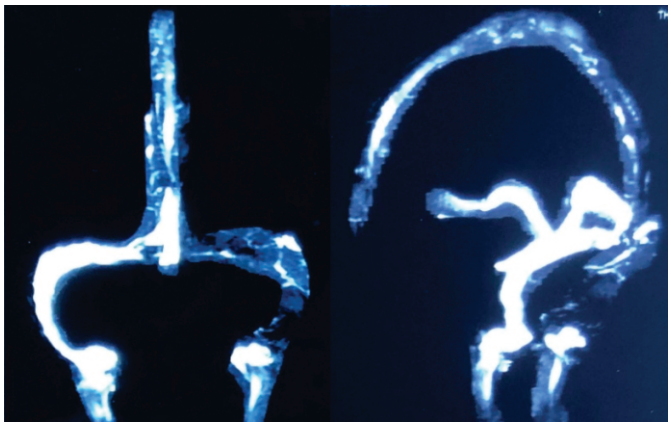

Fig. 3 MR venography shows filling defect in superior sagittal, right transverse and right sigmoid sinus.

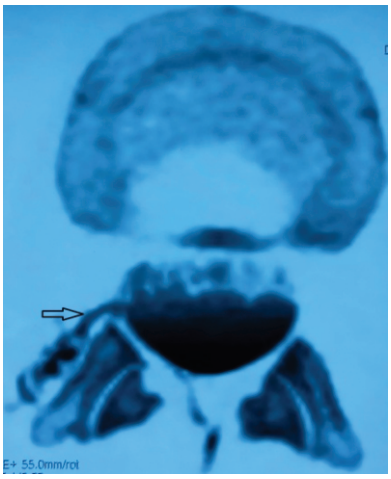

Fig. 4 CT myelography shows CSF leak at L1-2 level.

DISCUSSION

SIH is the result of spontaneous CSF leaks from dural rent, nerve root diverticula or CSF-venous fistula. Risk factors are hereditary (Ehlers-Danlos syndrome or Marfan syndrome), acquired (trauma) or iatrogenic (significant weight loss as in post bariatric surgery patient, lumbar puncture, spinal anesthesia or chiropractic manipulation)[3]. Most common site for CSF leak is cervicothoracic junction and rarely lower thoraco-lumbar spine or cranial.

As stated by Monro-Kellie hypothesis, total intracranial volume remains constant and three components (Parenchyma, CSF and blood) exist in equilibrium to maintain intracranial pressure in an intact skull. So, decrease in CSF volume (due to CSF leak) is compensated by venous engorgement as veins are more distensible. This explains most of brain MRI features in patient of SIH. Neuroimaging shows typical diffuse pachymeningeal gadolinium enhancement[5] due to increased venous blood volume. Other findings may include atraumatic subdural fluid, hematoma/hygroma, pituitary hyperemia, brain sagging (low lying cerebellar tonsil, flattening of the ventral pons, decreased pontomamillary distance, effacement of subarachnoid spaces including prepontine and perichiasmatic cisterns) and extradural fluid collections in spinal cord.

SIH associated with CVST is a very rare entity and only few case reports exist in literature[6,7]. SIH leading to CVST can be explained by several mechanisms. Most common being reduced blood flow velocity due to venous engorgement caused by continuous CSF leak. CSF absorption also reduces (due to decrease CSF volume) leading to increased blood viscosity. Characteristic brain sagging of SIH can cause stretching of venous outflow tracts (worsening venous expansion) and damage endothelial linings (alter CSF absorption capacity). These multiple factors predispose to formation of thrombus in venous sinuses[5].

SIH improves spontaneously in most of cases with bed rest, adequate hydration and caffeine. If symptoms persist, EBP is gold standard[8]. While management guidelines of CVST consist of anticoagulation and treatment of primary etiology.

Management of CVST with SIH imposes a therapeutic dilemma as anticoagulation can worsen already present suduraleffusion/hematoma and complicate condition[9,10]. In most case studies, SIH was treated with conservative approach while anticoagulation was used for CVST. Most common CSF leak site was cervicothoracic region and EBP was done in 1/3rd cases only.

In our case, patient had orthostatic headache for 5-6 years and prior MRI brain suggested SIH. Her recent exacerbation of headache which persisted in supine position, later turned out to be CVST (treated with anticoagulation). Our case further enriches the understanding of rare complication of SIH with CVST. Other unique feature to our case was the nontraumatic, lumbar site of CSF leak and the use of more effective targeted EBP for SIH.

CONCLUSION

Our case highlights early identification of change in headache symptomatology helps in diagnosing and treatment of potentially life threatening but treatable condition. Treatment of SIH complicated by CVST is difficult but careful approach with anticoagulation for CVST and targeted EBP for SIH can lead to a good outcome.

REFERENCES

1. Headache Classification Committee of the International Headache Society (IHS). The International Classification of Headache Disorders, 3rd edition. Cephalalgia. 2018;38(1):1–211 New criteria of diagnosis of SIH.
2. Schievink WI, Maya MM, Louy C, Moser FG, Tourje J. Diagnostic criteria for spontaneous spinal CSF leaks and intracranial hypotension. AJNR Am J Neuroradiol. 2008;29(5):853-6.
3. Upadhyaya P, Ailani J. A Review of Spontaneous Intracranial Hypotension. CurrNeurolNeurosci Rep. 2019 Mar 19;19(5):22.
4. Schievink WI, Maya MM. Cerebral venous thrombosis in spontaneous intracranial hypotension. Headache 2008;48:1511–9.
5. Bond K.M., Benson J.C, Cutsforth-Gregory J.K., Kim D.K., Diehn F.E., Carr C.M. Spontaneous Intracranial Hypotension: Atypical Radiologic Appearances, Imaging Mimickers, and Clinical Look-Alikes. American Journal of Neuroradiology. 2020 Aug;41(8):1339-47.

6. Yamamoto, A., Hattammaru, Y. &Uezono, S. Spontaneous intracranial hypotension associated with cerebral venous thrombosis detected by a sudden seizure: a case report. *JA Clin Rep.* 2020; 6: 59.

7. Zhang D, Wang J, Zhang Q, et al. Cerebral venous thrombosis in spontaneous intracranial hypotension: a report on 4 cases and a review of the literature. Headache. 2018;58:1244–55

8. Fei-Fang He, Li Li, Min-Jun Liu, Tai-Di Zhong, Qiao-Wei Zhang, Xiang-Ming Fang. Targeted Epidural Blood Patch Treatment for Refractory Spontaneous Intracranial Hypotension in China. J NeurolSurg B Skull Base. 2018 Jun;79(3):217-23.

9. Kataoka H, Tanizawa E, Ueno S. Spontaneous intracranial hypotension is associated with a risk of venous sinus thrombosis and subdural hematoma. Cerebrovasc Dis. 2007;23(4):315-7.

10. Min Ok Kim, Juhyeon Kim, Jongsoo Kang, Chang Hun Kim, Young-Soo Kim, Heeyoung Kang et al. Spontaneous Intracranial Hypotension as a Cause of Subdural Hematoma in a Patient with Cerebral Venous Thrombosis on Anticoagulation Treatment. J Clin Neurol. 2020 Apr; 16(2): 327–9.